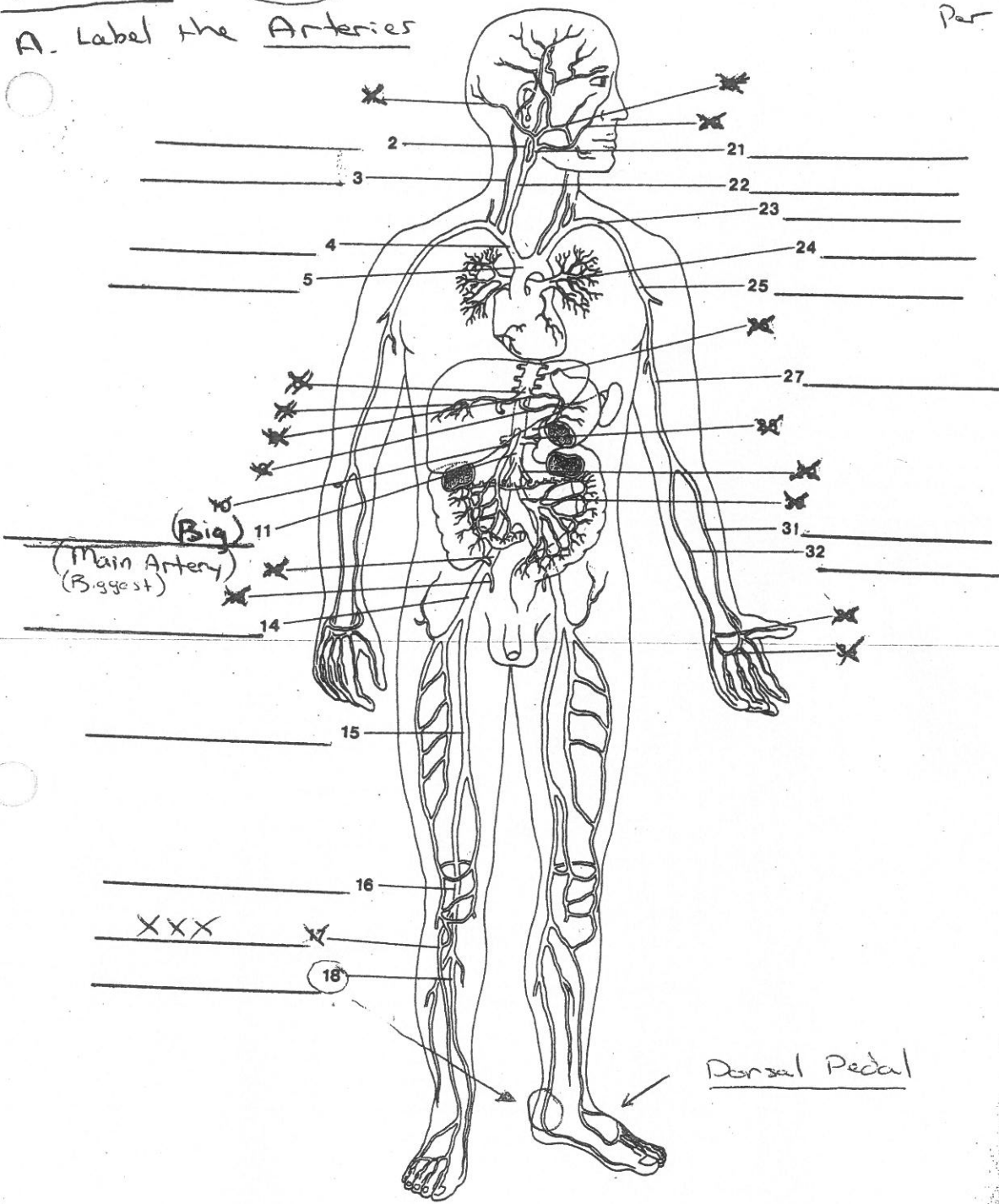


A. Label the Arteries



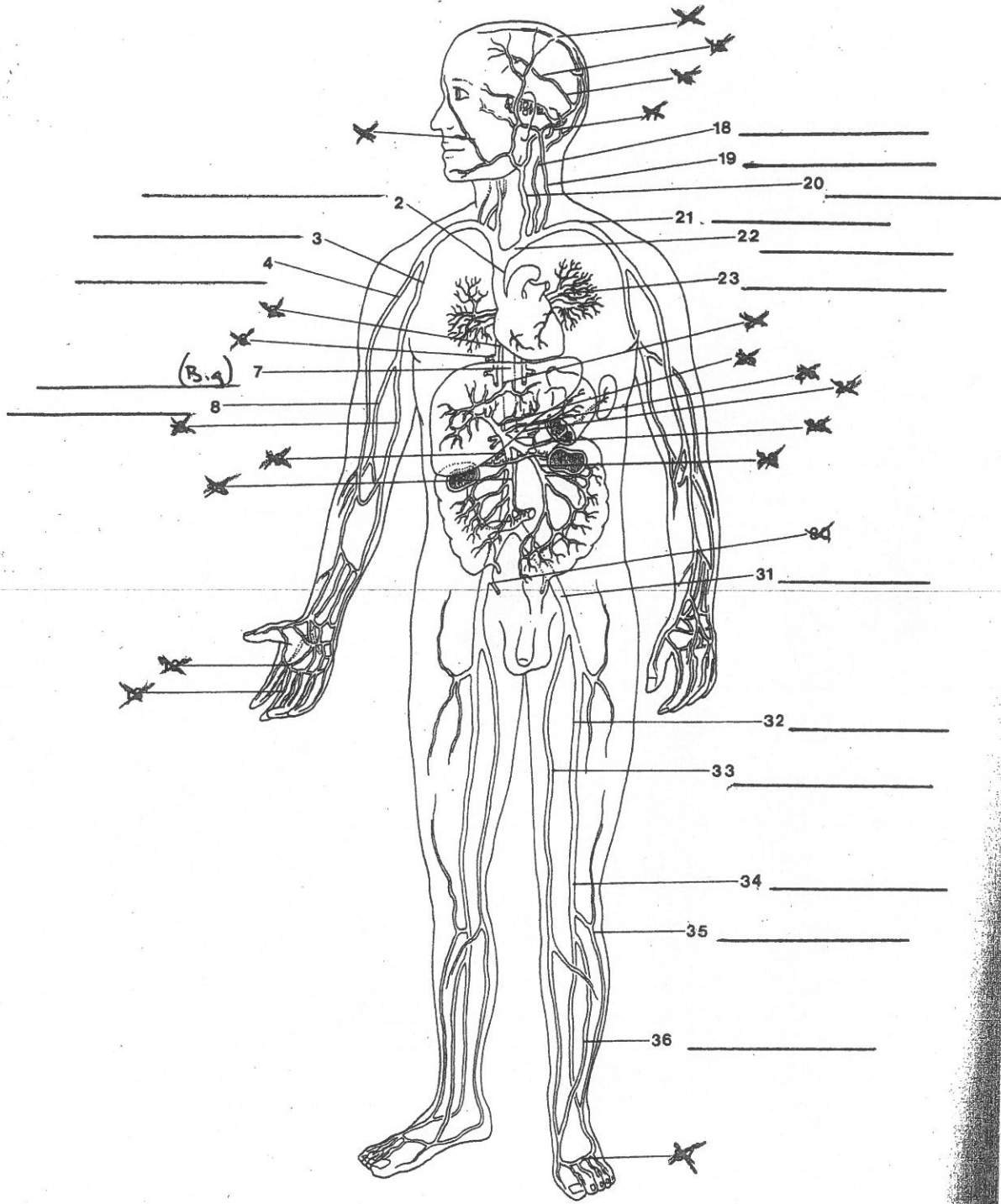
B.

Name the part of the body supplied by each of these arteries.

- | | |
|------------------------------|--------------------------------|
| 1) Coronary a. _____ | 10) Subclavian a. _____ |
| 2) Femoral a. _____ | 11) Radial a. _____ |
| 3) Brachial a. _____ | 12) Superior mesenteric a. XXX |
| 4) Bronchial a. XXX | 13) Esophageal a. XXX |
| 5) Internal carotid a. _____ | 14) Vertebral a. _____ |
| 6) Renal a. XXX | 15) Celiac a. XXX |
| 7) Hepatic a. _____ | 16) Popliteal a. XXX |
| 8) Intercostal a. XXX | 17) Common iliac a. _____ |
| 9) Anterior tibial a. _____ | 18) Plantar arches XXX |

Following is a diagram of the body in anterior view.

C. Label the veins indicated. (P. 380)



D.

Name the part of the body drained of blood by each of these veins.

- | | |
|----------------------------------|--------------------------------------|
| 1) External jugular v. _____ | 7) Cranial venous sinuses <u>XXX</u> |
| 2) Axillary v. _____ | 8) Superior vena cava _____ |
| 3) Great saphenous v. <u>XXX</u> | 9) Renal v. <u>XXX</u> |
| 4) Inferior vena cava _____ | 10) Subclavian v. _____ |
| 5) Common iliac v. _____ | 11) Brachial v. _____ |
| 6) Ulnar v. _____ | 12) Femoral v. _____ |